

## CASO CLÍNICO/CASE REPORT

**Tumor Recurrence versus Radiation-induced Stroke in a Child with a History of Medulloblastoma****Recidiva Tumoral versus AVC Secundário a Radioterapia numa Criança com Antecedentes de Medulloblastoma**

 Carolina Maia <sup>1,\*</sup>,  Joana Pinto <sup>1</sup>,  Sílvia Carvalho <sup>1</sup>,  Alice Carvalho <sup>2</sup>,  Filipe Palavra <sup>3</sup>

1-Medical Image Department – Neuroradiology Functional Unit, Centro Hospitalar e Universitário de Coimbra, Coimbra, Portugal

2-Oncology Department, Hospital Pediátrico, Centro Hospitalar e Universitário de Coimbra / Centro Hospitalar e Universitário de Coimbra, Coimbra, Portugal

3-Centre for Child Development – Neuropediatrics Unit, Hospital Pediátrico, Centro Hospitalar e Universitário de Coimbra; University of Coimbra, Coimbra Institute for Clinical and Biomedical Research (ICBR), Faculty of Medicine / Centro Hospitalar e Universitário de Coimbra, Coimbra, Portugal

DOI: <https://doi.org/10.46531/sinapse/CC/220076/2023>

**Informações/Informations:**

Caso Clínico, publicado em Sinapse, Volume 23, Número 2, abril-junho 2023. Versão eletrónica em [www.sinapse.pt](http://www.sinapse.pt); Case Report, published in Sinapse, Volume 23, Number 2, April-June 2023. Electronic version in [www.sinapse.pt](http://www.sinapse.pt)  
© Autor (es) (ou seu (s) empregador (es)) e Sinapse 2023. Reutilização permitida de acordo com CC BY-NC. Nenhuma reutilização comercial. © Author(s) (or their employer(s)) and Sinapse 2023. Re-use permitted under CC BY-NC. No commercial re-use.

**Keywords:**

Child;  
Medulloblastoma/radiotherapy;  
Radiation Injuries/  
complications;  
Stroke/etiology.

**Palavras-chave:**

Acidente Vascular Cerebral/  
etiologia;  
Criança;  
Lesões por Radiação/  
complicações;  
Medulloblastoma/radioterapia.

**\*Autor Correspondente / Corresponding Author:**

Carolina Maia  
Praceta Professor Mota Pinto  
3004-561 Coimbra, Portugal  
[carolinamaia.areal@gmail.com](mailto:carolinamaia.areal@gmail.com)

Recebido / Received: 2022-12-08

Aceite / Accepted: 2023-05-12

Publicado / Published: 2023-07-18

**Abstract**

Children with a history of central nervous system neoplasia, submitted to radiotherapy, have an increased risk of vascular complications that can be, clinically and imagiologically, very similar to a tumor recurrence.

We describe the case of an 11-year-old child who, 10 years after diagnosis and treatment of a medulloblastoma, suddenly developed right hemiparesis. The initial imaging findings did not allow the exclusion of tumor recurrence, making a differential diagnosis with recent ischemic injury. Due to clinical and imaging worsening, the patient started chemotherapy, suspended after the first cycle, due to clear neurological improvement. One month after the onset of symptoms, patient was clinically stable, having undergone a new magnetic resonance imaging, revealing a chronic evolution of the lesion, suggestive of a vascular etiology.

This case explores the differential diagnosis of late tumor recurrence in children undergoing radiotherapy, highlighting the importance of etiological identification in therapeutic guidance.

**Resumo**

As crianças com antecedentes de neoplasia do sistema nervoso central, submetidas a radioterapia, apresentam um risco aumentado de complicações vasculares que podem ser, clínica e imagiológicamente, muito semelhantes a uma recidiva tumoral.

Descrevemos o caso de uma criança de 11 anos que, 10 anos após diagnóstico e tratamento de um medulloblastoma, iniciou subitamente uma hemiparésia direita. Os achados imagiológicos iniciais não permitiram a exclusão de recidiva tumoral, fazendo diagnóstico diferencial com lesão vascular isquémica recente. Por agravamento clínico e imagiológico, o doente iniciou quimioterapia, suspensa após o primeiro ciclo, por melhoria neurológica franca. Um mês após o início do quadro, o doente encontrava-se clinicamente estável, tendo realizado nova ressonância magnética, que revelou evolução sequelar da lesão, sugestiva de ter, assim, etiologia vascular.

Este caso explora o diagnóstico diferencial de recidiva tumoral tardia em crianças submetidas a radioterapia, realçando a importância da identificação etiológica na orientação terapêutica.

## Introduction

Stroke is increasingly recognized as an important late effect in pediatric brain tumor survivors. The Childhood Cancer Survival Study, a multi-institutional retrospective cohort study of 14 358 five-year survivors of childhood cancers, has showed an increase rate of stroke in this population. Age-adjusted stroke rate was 77 per 100 000 (95% cumulative incidence 62-96), compared to 9.3 (95% cumulative incidence 4-23) for siblings, and treatment with cranial radiation therapy (CRT) increased stroke risk.<sup>1</sup>

In the acute phase, CRT leads to detachment of endothelium, splitting of basement membranes, and subintimal foam cell formation. Atherosclerotic-like changes of the medial layer and progressive adventitia fibrosis then follow, leading ultimately to steno-occlusion of irradiated arteries years after the initial therapy.<sup>2</sup> Radiation vasculopathy includes carotid stenosis, intracranial vessel stenosis, vasculitis, and cerebral ischemia. Dysplastic vascular organization, such as moyamoya patterns of transdural vessel anastomoses, and vascular abnormalities, such as aneurysms and cavernous malformations, are also observed.<sup>1,3</sup> Risk factors for radiation-induced vasculopathy in general include young age at the time of radiotherapy, radiation dose, focal irradiation that includes the circle of Willis and concurrent alkylating chemotherapy with radiotherapy.<sup>2</sup> Although vessel rupture and other acute injuries are less common findings with modern treatments, occlusive vasculopathies are now being seen years after initial radiotherapy with an increased incidence because of improved overall oncological treatments and patient survival. The latency time from radiation to the discovery of vasculopathy ranges broadly from 2 to 25 years.<sup>4</sup>

The appearance of radiation-induced vasculopathy and stroke on magnetic resonance imaging (MRI) and computed tomographic (CT) scans and its associated clinical symptoms are very similar to brain tumor recurrence,<sup>5-7</sup> and therefore differentiating these two conditions is a central challenge in neuro-oncology. Here we present a paradigmatic case addressing this clinical and imaging difficulty.

## Case Report

An 11-year-old boy presented to our institution in March 2019 with a 4-days history of right-sided weakness. His medical history was remarkable for medulloblastoma diagnosed at 17 months of age, which was submitted to resection and Headstart II Protocol (bone marrow autotransplantation and craniospinal radiation of 54Gy to the posterior fossa). Additional history included obesity

(body mass index greater than 97<sup>th</sup> percentile) and treatment-related complications namely coordination changes with fine tremor, discrete ataxia, left sixth nerve palsy and learning difficulties. His last MRI, 2 months before the event, did not demonstrate residual or recurrent tumor, before or after contrast administration.

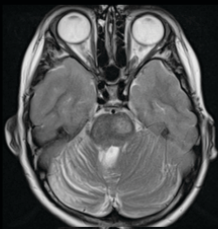
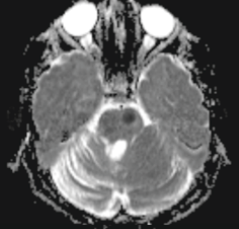
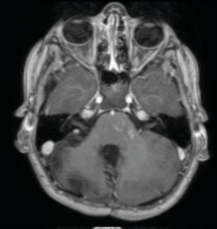
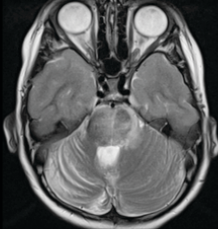
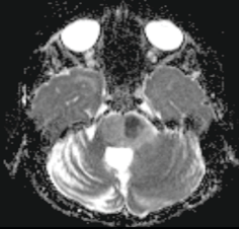
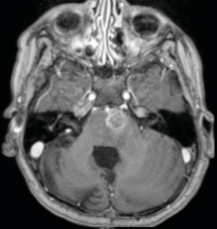
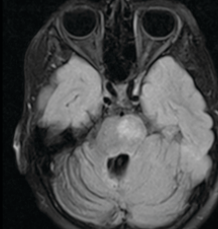
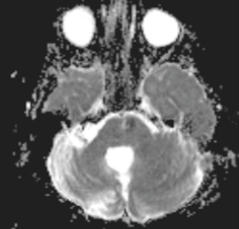

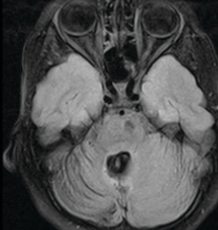
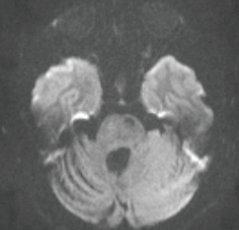
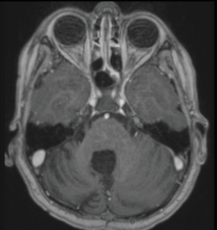
Four days prior to hospital presentation, the family noticed right arm weakness with difficulties in writing and, one day after, an additional involvement of the right leg. Symptoms persisted in the next days and the family came to the emergency department. His neurological examination showed facial asymmetry with left lower facial weakness, muscle tone was normal, but he had right hemiparesis, with the arm (4/5) affected more than the leg (4+/5). Deep tendon reflexes were difficult to elicit, and cutaneous plantar reflex was indifferent on the right. The remaining neurological examination was superimposed on what was already known, considering his regular follow-up in an Oncology consultation. Laboratory workup showed normal complete blood count, prothrombin time and partial thromboplastin time.

Urgent brain MRI was performed and showed heterogeneous signal changes involving the left cerebral and cerebellar peduncles, the left median cerebellar white matter, the left paramedian pons and the ipsilateral margin of the medulla oblongata. The pons lesion presented marked restricted diffusion in diffusion-weighted images. Heterogeneous but low intensity gadolinium-enhancement was seen in the referred locations (**Fig.1**). ThreeD time-of-flight (TOF) MR angiogram (MRA) showed no obvious vascular lesion. These findings were suggestive of an acute/subacute infarction, although did not rule out the possibility of high-cellularity tumor recurrence.

On hospital day 10, he continued to progress with worsening of the right hemiparesis (with grade 2/5), asymmetric appendicular ataxia and dysphagia. The brain MRI was repeated, showing further enlargement of the known lesions, as well as the previous described gadolinium enhancement. In the left paramedian pons an area of clear diffusion restriction persisted, with a lower signal in T2 and FLAIR and with gadolinium-enhancement more intense and larger, compared with the previous study (**Fig.1**).

Due to apparently relentless clinical worsening and taking into account the distinct progressive imaging findings in 10 days, with a tumefactive aspect that was not expected in a subacute ischemic lesion, we decided to initiate chemotherapy assuming tumor recurrence (ifosfamide, carboplatin and etoposide).

From day 20 of hospitalization (10 days after the

Brain MRI	Findings	T2/ FLAIR	DWI/ADC	T1 post-GAD
Initial study	T2/ FLAIR hyperintense lesions in the brainstem. Left paramedian pons lesion had restricted diffusion (low signal on ADC) and heterogeneous but low intensity gadolinium-enhancement.			
Ten days later	Marked increase of the signal changes that involved almost all of the pons, with a tumefactive aspect. An area of clear diffusion restriction persists, with gadolinium-enhancement more intense and larger.			
One month later	Volume decrease, minimal restricted diffusion and less gadolinium-enhancement of the known lesions.			
Six months later	T2/ FLAIR small hypointense lesion in the left paramedian pons with low DWI signal and no gadolinium-enhancement.			

**Figure 1.** Brain MRI scans of the reported case.

start of chemotherapy), patient's overall clinical picture started to improve significantly and the brain MRI was then repeated, one month after clinical onset, showing volume decrease of the known lesions, less gadolinium-enhancement and minimal restricted diffusion, which was compatible with the evolution of an ischemic vascular lesion (**Fig.1**). Taking into account this clinical and imaging evolution, we decided to suspend the chemotherapy after the first cycle. Considering this (a final diagnosis of stroke), the patient was then discharged home, four weeks after admission.

His stroke risk factor workup showed normal hemoglobin A1c and elevated low-density lipoprotein at 148 mg/dL. His obesity and hyperlipidemia were considered likely contributing factors for stroke. Given his high risk of recurrence in the setting of radiation-induced vasculopathy and hyperlipidemia, he was started on lipid-lowering therapy. Use of antiplatelet therapy (e.g., acetylsalicylic acid) was discussed in a multidisciplinary meeting, being

decided to delay its start, considering the risk of bleeding events in a young patient that practices combat sports.

By the sixth month of follow-up, the patient continued with a functional rehabilitation plan, maintaining progressive improvement, the clinical observation did not reveal any new focal neurological deficit and the MRI findings have improved significantly, with normal evolution of the ischemic lesions into chronic end-stage sequelae (**Fig.1**).

At the present moment, he remains being monitored by Oncology and Neurology.

## Discussion

Children with central nervous system tumors who receive CRT are at increased risk for vascular complications.<sup>1,2</sup> Here we presented a case with an initial clinical picture and imaging features consistent with acute-sub-acute infarction. However, the progressive worsening of the clinical status and the atypical evolution of the vascular lesions identified in the MRI during the initial stage, led us

to consider the hypothesis of tumor recurrence and to start chemotherapy. This case highlights not only the diagnostic difficulties between radiation-induced vasculopathy and tumor recurrence, but also increases awareness for primary and secondary prevention for cerebrovascular disease after radiotherapy.

CRT is one of the main treatment modalities for central nervous system tumors, being part of the standard therapy of medulloblastoma patients. Long-term complications of radiation have gained more relevance, as there has been an increase in overall survival of medulloblastoma patients over the past 20 years, due to improvements in the quality of care.<sup>2,8</sup> Vasculopathy affecting medium and large intra- and extra-cranial arteries is one of the most prominent late sequelae of CRT and, according to Haddy and colleagues, the radiation applied to the prepontine cistern has a higher impact for the development of cerebrovascular disease than a similar radiation dose to any other part of the brain.<sup>9</sup> However, despite the impact of this condition in medulloblastoma survivors, it is often underrecognized and poorly managed.<sup>2,8</sup>

The appearance of radiation-induced vasculopathy on imaging and its associated clinical symptoms could be very similar to brain tumor recurrence, and therefore, it is difficult to differentiate between the two outcome types. Currently, the gold standard for distinguishing is biopsy, which has an accuracy and specificity of more than 95%.<sup>5,6</sup> However, biopsy is an invasive strategy and has numerous potential complications, such as infection, bleeding, and other neurological problems. In fact, the performance of this procedure was discussed in our case in a multidisciplinary meeting, but ruled out, taking into account the high complication rate of brainstem biopsy.

Although several studies have reported specific features on MRI to either radiation changes or tumor recurrence, no feature or combination of features has been established as a reliable discriminator between these two outcomes. Some of the imaging features most reported to be shared by tumor recurrence and radiation vasculopathy include, as in our case, origin near the primary tumor site, contrast-agent enhancement, edema, and mass effect.<sup>5-7</sup>

Diffusion imaging could be helpful in differentiating stroke from tumor recurrence since the vast majority of neoplasms do not restrict diffusion or change it only mildly, but the clinician should be aware of some limitations. Although restricted diffusion is the hallmark imaging feature of acute cerebral infarction, usually developing within 1 hour of insult and returning to normal by 10-14 days, a few tumors with high cellularity, including medul-

loblastoma, may show significant diffusion restriction and thus appear remarkably bright on DW images.<sup>10</sup> So, the marked restricted diffusion of the lesion that we found in our patient, did not allow us to exclude the recurrence of medulloblastoma.

Case reports have described delayed postradiation vasculopathy in children with treated medulloblastoma. Small vessels and capillaries are more vulnerable than large vessels, showing arterial wall irregularities and focal stenoses.<sup>14</sup> Although our patient had performed an MRA with no obvious vascular injury, we could not rule out the possibility of small-vessel disease with this technique. Actually, one of the known limitations of MRA is its lack of sensitivity in the detection of distal arterial lesions.<sup>15</sup> Previous studies reported that digital subtraction angiography (DSA) should be considered in situations in which MRA is normal and small-artery diseases are suspected.<sup>4,16</sup> The performance of this exam was considered in our patient, but we chose to delay it, considering several disadvantages in a child: it is invasive, requires sedation, large amount of contrast agent and relatively high radiation dose.

Despite the advances in medulloblastoma treatment, approximately 30% of these patients recur and prognosis following relapse is extremely poor, with early detection of relapse being associated with increased survival in these children.<sup>6</sup> In the light of this data, we decided to start chemotherapy in our patient since his clinical status deteriorated markedly in the first days and the MRI could not rule out the hypothesis of tumor recurrence.

With an increased survival of cancer patients, the potential benefit of more aggressive preventive strategies for this high-risk group of patients needs to be further investigated. Evidence-based guidelines for the management of asymptomatic and symptomatic radiation vasculopathy are lacking.<sup>17</sup> CRT is significantly associated with increased incidence of obesity, raised blood pressure, hypercholesterolemia, and dyslipidemia in childhood brain tumor survivors.<sup>18</sup> In view of the noted high recurrent stroke risk amongst these patients more intensive follow-up, as well as a more comprehensive neurovascular workup should be implemented. Vascular imaging to detect intra and extra-cranial vasculopathy (particularly amongst patients with head and neck cancers treated with radiotherapy) should be considered for all cancer patients who present with ischemic stroke. Furthermore, since the risk of recurrent stroke is disproportional to conventional risk factors,<sup>13</sup> alternative variables should be considered. No trial to date has adequately assessed the medical treatment options in primary or secondary stroke prevention in this patient group. The effect of antiplatelet, anticoagulant,

antihypertensive, or lipid-lowering therapy in limiting disease progression is therefore unclear.<sup>17</sup>

In conclusion, we highlight the need to consider stroke as a result of delayed radiation-induced vasculopathy in the differential diagnosis of new mass-like MRI findings in patients previously treated with CRT. Our patient's presentation with stroke symptoms and imaging findings resembling lacunar syndromes commonly seen in older adults suggests that radiation combined with other risk factors might accelerate the pathogenesis of small vessel disease. For future research, we hope there would be more focus on standardized treatment, screening and guidelines for this disease, especially for secondary stroke prevention, with a well-established approach to provide timely evidence-based care for such patients. ■

#### Contributorship Statement / Declaração de Contribuição

CM: study design and execution, manuscript elaboration.  
JP, FP: study design and execution, manuscript review.  
SC, AC: manuscript review.

#### Responsabilidades Éticas

Conflitos de Interesse: Os autores declaram a inexistência de conflitos de interesse na realização do presente trabalho.

Fontes de Financiamento: Não existiram fontes externas de financiamento para a realização deste artigo.

Confidencialidade dos Dados: Os autores declaram ter seguido os protocolos da sua instituição acerca da publicação dos dados de doentes.

Consentimento: Consentimento do doente para publicação obtido.

Proveniência e Revisão por Pares: Não comissionado; revisão externa por pares.

#### Ethical Disclosures

Conflicts of Interest: The authors have no conflicts of interest to declare.

Financing Support: This work has not received any contribution, grant or scholarship.

Confidentiality of Data: The authors declare that they have followed the protocols of their work center on the publication of data from patients.

Patient Consent: Consent for publication was obtained.

Provenance and Peer Review: Not commissioned; externally peer reviewed.

#### References / Referências

- Mueller S, Fullerton HJ, Stratton K, Leisenring W, Weathers RE, Stovall M, et al. Radiation, atherosclerotic risk factors, and stroke risk in survivors of pediatric cancer: a report from the Childhood Cancer Survivor Study. *Int J Radiat Oncol Biol Phys.* 2013;86:649-55. doi: 10.1016/j.ijrobp.2013.03.034.
- Murphy ES, Xie H, Merchant TE, Yu JS, Chao ST, Suh JH. Review of cranial radiotherapy-induced vasculopathy. *J Neurooncol.* 2015;122:421-9. doi: 10.1007/s11060-015-1732-2.
- Kim JH, Brown SL, Jenrow KA, Ryu S. Mechanisms of radiation-induced brain toxicity and implications for future clinical trials. *J Neurooncol.* 2008;87:279-86. doi: 10.1007/s11060-008-9520-x.
- Twitchell S, Karsy M, Guan J, Couldwell WT, Tausky P. Sequelae and management of radiation vasculopathy in neurosurgical patients. *J Neurosurg.* 2018:1-9. doi: 10.3171/2017.12.JNS172635.
- Omuro AM, Leite CC, Mokhtari K, Delattre JY. Pitfalls in the diagnosis of brain tumours. *Lancet Neurol.* 2006;5:937-48. doi: 10.1016/S1474-4422(06)70597-X.
- Verma N, Cowperthwaite MC, Burnett MG, Markey MK. Differentiating tumor recurrence from treatment necrosis: a review of neuro-oncologic imaging strategies. *Neuro Oncol.* 2013;15:515-34. doi: 10.1093/neuonc/nos307.
- Omura M, Aida N, Sekido K, Takechi M, Matsubara S. Large intracranial vessel occlusive vasculopathy after radiation therapy in children: clinical features and usefulness of magnetic resonance imaging. *Int J Radiat Oncol Biol Phys.* 1997;38:241-9. doi: 10.1016/s0360-3016(97)82497-2.
- Tanyildizi Y, Keweloh S, Neu MA, Russo A, Wingerter A, Weyer-Elberich V, et al. Radiation-induced vascular changes in the intracranial irradiation field in medulloblastoma survivors: An MRI study. *Radiother Oncol.* 2019;136:50-5. doi: 10.1016/j.radonc.2019.03.017.
- Haddy N, Mousannif A, Tukenova M, Guibout C, Grill J, Dhermain F, et al. Relationship between the brain radiation dose for the treatment of childhood cancer and the risk of long-term cerebrovascular mortality. *Brain.* 2011;134:1362-72. doi: 10.1093/brain/awr071.
- Finelli PF. Diagnostic approach to restricted-diffusion patterns on MR imaging. *Neurol Clin Pract.* 2012;2:287-93. doi: 10.1212/CPJ.0b013e318278bee1.
- Bansal LR, Belair J, Cummings D, Zuccoli G. Late-onset radiation-induced vasculopathy and stroke in a child with medulloblastoma. *J Child Neurol.* 2015;30:800-2. doi: 10.1177/0883073814538501.
- Grenier Y, Tomita T, Marymont MH, Byrd S, Burrowes DM. Late postirradiation occlusive vasculopathy in childhood medulloblastoma – report of two cases. *J Neurosurg.* 1998;89:460-4. doi: 10.3171/jns.1998.89.3.0460.