











CASO CLÍNICO/CASE REPORT

Susac Syndrome and COVID-19 Infection: A Two-Direction Therapeutic Dilemma**Síndrome de Susac e Infecção por COVID-19: Um Dilema Terapêutico de Duas Direções**

 Ana Baltasar Corral ¹,  Ana Fernández Revuelta ¹,  Vicente Gajate García ¹,  Marta García Yepes ¹,  Alberto Marcos Dolado ¹,  Eva López Valdés ¹,  Manuela Jorquera Moya ²,  Ramón Torres Imaz ³,  William Aragonés Sanzen-Baker ⁴,  Ricardo Constantino Ginestal Lopéz ^{1,*}

1-Servicio de Neurología / Hospital Universitario Clínico San Carlos, Madrid, España

2-Servicio de Radiología / Hospital Universitario Clínico San Carlos, Madrid, España

3-Servicio de Oftalmología / Hospital Universitario Clínico San Carlos, Madrid, España

4-Servicio de Otorrinolaringología / Hospital Universitario Clínico San Carlos, Madrid, España

DOI: <https://doi.org/10.46531/sinapse/CC/200057/2020>

Informações/Informations:

Caso Clínico, publicado em Sinapse, Volume 20, Número 4, outubro-dezembro 2020. Versão eletrónica em www.sinapse.pt

Case Report, published in Sinapse, Volume 20, Number 4, october-december 2020. Electronic version in www.sinapse.pt

© Autor (es) (ou seu (s) empregador (es)) e Sinapse 2020. Reutilização permitida de acordo com CC BY-NC. Nenhuma reutilização comercial. © Author(s) (or their employer(s)) and Sinapse 2020. Re-use permitted under CC BY-NC. No commercial re-use.

Keywords:

Coronavirus Infections; COVID-19; Susac Syndrome.

Palavras-chave:

COVID-19; Infecções por Coronavírus; Síndrome de Susac.

***Autor Correspondente / Corresponding Author:**

Ricardo Constantino Ginestal López
Hospital Clínico San Carlos,
Servicio de Neurología, Calle del Profesor Martín Lagos s/n, 28040 Madrid, España
rcginestal@yahoo.es

Recebido / Received: 2020-10-03

Aceite / Accepted: 2020-12-04

Ahead of Print: 2020-12-21

Publicado / Published: 2021-01-18

Abstract

Susac syndrome (SuS) is an autoimmune-mediated microvessel occlusion disease of the central nervous system, retina and inner ear. Treatment consists in the use of corticosteroids, intravenous immunoglobulin, mycophenolate mofetil, tacrolimus, rituximab and cyclophosphamide. Immunocompromised patients may be at higher risk of severe COVID-19 and, simultaneously, infections could exacerbate SuS disease activity. A 32 years-old female with extremely severe SuS, treated with a combination of mycophenolate mofetil, rituximab, cyclophosphamide and oral prednisone, developed a life-threatening COVID-19 infection. Immunosuppressants were stopped and anticoagulant therapy was instituted. Forty-one days after COVID-19 infection diagnosis, she was discharged with her neurological status unchanged. Even considering the life-threatening COVID-19 infection risk, maintaining combined immunosuppression is advised in an extremely severe SuS. Confirmation of COVID-19 infection would be the only reason to stop immunosuppressants. COVID-19 hypercoagulable state may increase thrombosis risk. Anticoagulant treatment is associated with COVID-19 lower mortality and, arguably, with a better prognosis of SuS.

Resumo

A síndrome de Susac (SuS) de mecanismo auto-imune, provoca oclusões microangiopáticas no encéfalo, retina e ouvido interno. Consoante a sua gravidade, o tratamento é uma combinação de corticóides, imunoglobulina intravenosa, micofenolato de mofetil, tacrolimus, rituximab e ciclofosfamida. A imunossupressão pode aumentar o risco de infecção grave por COVID-19. Concomitantemente, as infecções podem reactivar a SuS. Uma doente com uma SuS extremamente grave, tratada com micofenolato de mofetil, rituximab, ciclofosfamida e prednisona, desenvolveu uma infecção COVID-19 de risco vital. Os imunossupressores foram retirados e iniciaram-se anti-coagulantes. A doente teve alta sem mudanças no seu estado neurológico, 41 dias depois. Mesmo perante o risco duma infecção COVID-19 com risco vital, é recomendado manter os imunossupressores numa SuS extremamente grave. A confirmação do diagnóstico da infecção COVID-19 deveria ser o único motivo para retirar os imunossupressores. Os anticoagulantes melhoram o prognóstico da COVID-19 e deveriam ser especialmente ponderados se coincide com uma SuS.

Introduction

Susac syndrome (SuS) is a rare and disabling disorder caused by autoimmune-mediated microvessel occlusions in the central nervous system (CNS), retina and inner ear.¹ The treatment is based on the sequential use and/or combination of corticosteroids, intravenous immunoglobulin, mycophenolate mofetil, tacrolimus, rituximab and cyclophosphamide.²

Mortality from COVID-19 appears to be, principally, driven by age, gender and comorbidities such as obesity and smoking.³ It is also assumed that immunocompromised patients may be at higher risk of severe clinical presentations of infections such as COVID-19, through greater viral replication.⁴ Simultaneously, infections could exacerbate SuS disease activity, as infections do in other autoimmune diseases.⁵

Case Report

In January 2020, a 32 years-old female (smoker, 130 kg of body weight, body mass index 38) was admitted because of subacute behavioral changes, unexplained headache and gait impairment. Neuroimaging was key for diagnosis, showing rounded FLAIR and T2 hyperintense “snowball lesions” in the corpus callosum (**Fig. 1**).

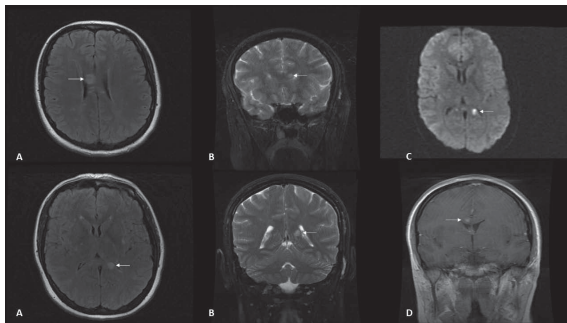


Figure 1. Brain magnetic resonance imaging scan

- A. Axial FLAIR-weighted images showing Susac's characteristic corpus callosum snowball lesions (arrows).
- B. Coronal T2-weighted images displaying corpus callosum body and splenium snowball lesions (arrows).
- C. Diffusion-weighted image: hyperintense lesion in the splenium of the corpus callosum (arrow).
- D. Coronal T1-weighted image: body of corpus callosum Gadolinium-enhancing lesion (arrow).

The classic triad of SuS, encephalopathy, peripheral retinal arterial branch occlusions and sensorineural hearing loss, confirmed the diagnosis. Initially, intravenous 1 g/day/5days methylprednisolone was administered. With no clinical improvement after the first pulse, she received 5 more days of methylprednisolone in addition to intravenous immunoglobulins (0.4 g/kg/day/5days). With

only very mild recovery, treatment was escalated to mycophenolate mofetil (1000 mg bid), two 1000 mg doses of rituximab (11th and 25th January) and oral prednisone (1 mg/kg/day, in this case not exceeding 80 mg/day, as recommended by Rennebohm *et al*²). Significant recovery was finally achieved, with independent walking, no headache and normal behavior. She was discharged on February 12. Treatment after discharge was mycophenolate mofetil (1000 mg bid), prednisone (80 mg/day), omeprazole (20 mg/day) and calcium carbonate/colecalciferol 1 pill/day.

Seventeen days after the last rituximab dose, and maintaining the same doses of mycophenolate mofetil and prednisone, she was readmitted. She had developed right hemiparesis/hypoesthesia and double incontinence. She was unable to walk. A significant worsening of executive functions was evident. Due to the extreme severity of this SuS, mycophenolate mofetil was discontinued and cyclophosphamide treatment (1300 mg, 10 mg/kg) was administered on March 5. Cyclophosphamide protocol was, following Rennebohm *et al* guidelines,² two initial doses of 10-15 mg/kg, two weeks apart. After these “per protocol” doses, treatment with cyclophosphamide was to be stopped and mycophenolate mofetil was to be reinitiated if improvement was considered satisfactory. If improvement was unsatisfactory, cyclophosphamide was to be continued with another 10-15 mg/kg dose in 2 weeks and then 10-15 mg/kg every 3weeks for 3 doses. Thereafter, 10-15 mg/kg doses were to be administered every 4 weeks for 1 to 3 more times. With a considerable improvement after the first cyclophosphamide administration, being able to walk unaided, controlling bladder and bowel functions, and with an almost normal cognitive testing examination, the patient was discharged on March 14. Treatment at discharge was prednisone 80 mg/day, omeprazole 20 mg/day, calcium carbonate/colecalciferol 1 pill/day, calcifediol 0,266 mg per month (vitamin D 15.960 UI) and trimethoprim-sulfamethoxazole 160/800 mg 1 pill/day.

The second dose of cyclophosphamide was scheduled on March 19. Vital signs were tested before administration. She had fever (38°C). No symptoms of COVID-19 were reported by the patient. Her neurological status was stable. Initial laboratory investigations showed an absolute lymphocyte count of 600 cells/ μ L, C-reactive protein of 5.21 mg/dL (normal range: 0.1 to 0.5), and D-dimer of 1016 ng/mL (normal range: 0.1 to 500).

Chest X-ray showed a bilateral ground glass opacity with associated linear atelectasis (**Fig. 2A**). Additional

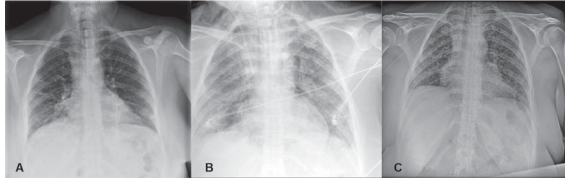


Figure 2. Chest X-ray evolution of our patient

- A. Bilateral peripheral chest opacities with basal atelectasis.
 B. Radiological worsening with extensive bilateral infiltrates. Subcutaneous cervical emphysema and 12 mm apical pneumothorax.
 C. Overall improvement, with predominance of bilateral interstitial infiltrates.

tests (electrocardiogram, arterial gasometry, computed tomography pulmonary angiogram) ruled out a pulmonary thrombotic event. SARS-CoV-2 PCR was positive. At that time, the patient was taking prednisone 80 mg per day and was maintained unchanged. The second dose of cyclophosphamide was then postponed. She was started on hydroxychloroquine (400 mg bid for the first 24 hours, 200 mg bid afterwards) and lopinavir/ritonavir 200/50 mg (2 pills every 12 hours). On March 23, azithromycin (500 mg/day) was added on the suspicion of bacterial lung superinfection, as per our hospital protocol regarding COVID-19 management. Pneumocystis jiroveci pneumonia was not suspected as the patient had been on trimethoprim-sulfamethoxazole since the previous hospitalization. On March 23, peripheral blood lymphocyte number was 500 cells/ μ l. Neurologically unchanged, the patient's respiratory condition worsened steadily. A progressive decrease in oxygen saturation (89% with FiO₂ 100% on March 26, up to a nadir of 70% on March 28) and absolute lymphocyte counts (nadir 200 cells/ μ l) occurred. Azithromycin was substituted by meropenem (1000 mg tid) due to the clinical deterioration and the suspected nosocomial lung superinfection in an immunocompromised patient. High dose intravenous (iv) methylprednisolone (1000 mg/day for three days) was started and a Boussignac continuous positive airway pressure was needed. Nevertheless, the patient was admitted to Intensive Care Unit on April 2 and intubated due to continued deterioration of her respiratory function. Her chest X-ray showed a marked deterioration of the lung infiltrates (**Fig. 2B**). A subcutaneous cervical emphysema and a 12 mm apical pneumothorax were seen due to a traumatic central venous catheter insertion. She was on mechanic ventila-

tion for five days. Because of high D-dimer levels (2459 ng/mL) and even in the absence of clinical or paraclinical evidence of pulmonary thrombosis, enoxaparin 60 mg bid (1 mg/kg/day) was prescribed for the prevention of thrombotic events in a high-risk ICU patient with a 5-fold increase of D-dimer levels and a body weight > 120 kg. She returned to the Pneumology ward, without new neurological symptoms, one week later. Finally, on April 28, after 41 days, the patient was discharged home with a marked improvement of the previously extensive bilateral infiltrates (**Fig. 2C**), no oxygen therapy, and no deterioration on her CNS neurological status compared to March 14. Enoxaparin 60 mg bid was stopped one month after discharge. She did not get a new MRI because SARS-CoV-2 PCR was still positive on June 2. As per September 8, the patient received a new dose of rituximab (1000 mg), and her neurological condition was stable.

Discussion

COVID-19 infection in SuS patients, particularly in those with combined immunosuppressive therapy, raises a two-direction therapeutic dilemma.

First, the effect of immunosuppressants on COVID-19 severity. Both combined immunosuppression and COVID-19 can lead to very low lymphocyte counts, resulting in bacterial superinfections and more severe COVID-19,⁶ as in our patient. However, recent reviews have presented, with limited data, that patients with multiple sclerosis (MS) treated with disease modifying drugs do not obviously have an increased risk of acquiring symptomatic SARS-CoV-2 infection.⁷ Similarly, mortality from COVID-19 in cancer patients seems to be principally related to age, gender and comorbidities and not to cytotoxic chemotherapy.⁸ Not all immunosuppressive drugs have the same impact on COVID-19 severity. Mycophenolate mofetil is likely to cause more harm than benefit.⁹ On the contrary, recent reviews have presented, with small series of patients, that individuals with MS treated with fingolimod¹⁰ or anti-CD20 monoclonal antibodies¹¹⁻¹³ could have milder forms of COVID-19 infection because of a dampened "cytokine storm syndrome".⁷ Nevertheless, a recently presented study by Sormani *et al*¹⁴ reveals the opposite, that the use of anti-CD20 agents (ocrelizumab or rituximab) was significantly associated with an increased risk of severe COVID-19 course. Data for cyclophosphamide are scant.

Second, the effect of COVID-19 infection on SuS evolution. The cytokine storm syndrome could hypothetically reactivate SuS and, therefore, the use of immunosuppressants may be needed for preventing a severe relapse of the autoimmune disease. Moreover, SARS-CoV-2 induced complement hyperactivation, endothelial dysfunction and cytokine storm have a prothrombotic effect. COVID-19 patients develop a pro-coagulative state directly related to disease severity.¹⁵ The COVID-19-related hypercoagulable state may increase the risk of ischaemic lesions, both micro- and macrovascular thrombosis.¹⁶ Strokes have been reported to be prevalent among patients with COVID-19. The cause is not clear but the COVID-19 associated “sepsis-induced coagulopathy” (SIC) may contribute to endothelial dysfunction, microthrombosis, and stroke. There is some evidence that low molecular weight heparins may be useful in the SIC hypercoagulable state associated with COVID-19¹⁷ and that anticoagulant treatment is associated with lower mortality.¹⁵ In this line of thought, a recent review by the Mayo Clinic Evidence-based Practice Center recommends the use of 40 mg subcutaneous enoxaparin twice daily for COVID-19 patients with more than 120 kg of weight residing in the clinical ward for the prevention of thrombosis. For Intensive Care Unit high-risk patients with D-dimer values exceeding 3.0 mg/mL the same approach to prophylaxis should be considered with enoxaparin, 40 mg twice daily for patients > 120 kg of body weight.¹⁸

Even with a severe COVID-19 infection, our patient’s SuS clinical condition did not get worse. Probably, even if therapeutic decision-making is more challenging during the COVID-19 pandemic, maintaining combined immunosuppression is clinically justified in an extremely severe SuS to control disease evolution, assuming the risk of getting infected by SARS-CoV-2. Confirmation of COVID-19 infection would be the only reason to stop immunosuppressants, in order to avoid a more severe infection. More information on the precise effect of the different immunosuppressants on COVID-19 is needed to make evidence-based decisions. Regarding anticoagulants, not only for the general prognosis of a severe COVID-19 disease, but also taking into consideration the underlying SuS, which causes occlusions in microvessels in the CNS, retina and inner ear, the early use of anticoagulation should be weighed.

The very low prevalence of SuS will not allow to have

large registries of patients with SuS and COVID-19 infection. Therefore, therapeutic decisions will have to be made on the basis of SuS isolated clinical reports and on the data of more prevalent immunosuppressant-treated conditions such as MS or cancer. ■

Responsabilidades Éticas

Conflitos de Interesse: Os autores declaram a inexistência de conflitos de interesse na realização do presente trabalho.

Fontes de Financiamento: Não existiram fontes externas de financiamento para a realização deste artigo.

Confidencialidade dos Dados: Os autores declaram ter seguido os protocolos da sua instituição acerca da publicação dos dados de doentes.

Consentimento: Consentimento do doente para publicação obtido.

Proveniência e Revisão por Pares: Não comissionado; revisão externa por pares.

Ethical Disclosures

Conflicts of Interest: The authors have no conflicts of interest to declare.

Financing Support: This work has not received any contribution, grant or scholarship.

Confidentiality of Data: The authors declare that they have followed the protocols of their work center on the publication of data from patients.

Patient Consent: Consent for publication was obtained.

Provenance and Peer Review: Not commissioned; externally peer reviewed.

References / Referências

- N1. Vishnevskia-Dai V, Chapman J, Sheinfeld R, Sharon T, Huna-Baron R, Manor RS, et al. Susac syndrome: clinical characteristics, clinical classification, and long-term prognosis. *Medicine*. 2016; 95: e5223. doi:10.1097/MD.0000000000005223.
- Rennebohm RM, Asdaghi N, Srivastava S, Gertner E. Guidelines for treatment of Susac syndrome - An update. *Int J Stroke*. 2018; 1747493017751737. doi:10.1177/1747493017751737.
- Ruan Q, Yang K, Wang W, Jiang L, Song J. Clinical predictors of mortality due to COVID-19 based on an analysis of data of 150 patients from Wuhan, China. *Intensive Care Med*. 2020; 46: 846-8. doi:10.1007/s00134-020-05991-x.
- Grebenciucova E, Pruitt A. Infections in Patients Receiving Multiple Sclerosis Disease-Modifying Therapies. *Curr Neurol Neurosci Rep*. 2017; 17: 88. doi:10.1007/s11910-017-0800-8.
- Panitch HS. Influence of infection on exacerbations of multiple sclerosis. *Ann Neurol*. 1994; 36 Suppl: S25-S28. doi:10.1002/ana.410360709.
- Sá MJ. Neuromyelitis Optica Spectrum Disorders and COVID-19. *Sinapse*. 2020;20:34-36. doi: 10.46531/sinapse/AR/COVID19/SaMJ/2020.
- Berger JR, Brandstadter R, Bar-Or A. COVID-19 and MS disease-modifying therapies. *Neurol Neuroimmunol Neuroinflamm*. 2020; 7: e761. doi:10.1212/NXI.0000000000000761.
- Lee LYW, Cazier JB, Starkey T, Arnold R, Bisht V, Campton NA, et al. COVID-19 mortality in patients with cancer on chemotherapy or other anticancer treatments: a prospective cohort study. *Lancet*. 2020 (in press). doi:10.1016/S0140-6736(20)31173-9.
- Russell B, Moss C, George G, Santaolalla A, Cope A, Papa S, et al. Associations between immune-suppressive and stimulating drugs and novel COVID-19-a systematic review of current evidence. *Ecancermedscience*. 2020; 14: 1022.

- doi:10.3332/ecancer.2020.1022.
10. Barzegar M, Mirmosayyeb O, Nehzat N, Sarrafi R, Khorvash F, Maghzi AH, et al. COVID-19 infection in a patient with multiple sclerosis treated with fingolimod. *Neurol Neuroimmunol Neuroinflamm.* 2020; 7: e753. doi:10.1212/NXI.0000000000000753.
 11. Giovannoni G. Anti-CD20 immunosuppressive disease-modifying therapies and COVID-19. *Mult Scler Relat Disord.* 2020; 41: 102135. doi:10.1016/j.msard.2020.102135.
 12. Montero-Escribano P, Matías-Guiu J, Gómez-Iglesias P, Porta-Etessam J, Pytel V, Matias-Guiu JA. Anti-CD20 and COVID-19 in multiple sclerosis and related disorders: A case series of 60 patients from Madrid, Spain. *Mult Scler Relat Disord.* 2020;42:102185. doi: 10.1016/j.msard.2020.102185.
 13. Louapre C, Collongues N, Stankoff B, Giannesini C, Papeix C, Bensa C, et al. Covisep investigators. Clinical characteristics and outcomes in patients with coronavirus disease 2019 and Multiple Sclerosis. *JAMA Neurol.* 2020;77:1079-88. doi: 10.1001/jamaneurol.2020.2581.
 14. Sormani, MP, De Rossi N, Schiavetti I, Carmisciano L, Cordioli C, Moiola L, et al. Musc-19 Study Group. Disease Modifying Therapies and COVID-19 Severity in Multiple Sclerosis [accessed 6/15/2020] Available at SSRN: <https://ssrn.com/abstract=3631244> or <http://dx.doi.org/10.2139/ssrn.3631244>.
 15. Carfora V, Spiniello G, Ricciolino R, Di Mauro M, Migliaccio MG, Mottola FF, et al. COVID-19 group. Anticoagulant treatment in COVID-19: a narrative review. *J Thromb Thrombolysis.* 2020 (in press). doi: 10.1007/s11239-020-02242-0.
 16. Abou-Ismaïl MY, Diamond A, Kapoor S, Arafah Y, Nayak L. The hypercoagulable state in COVID-19: Incidence, pathophysiology, and management. *Thromb Res.* 2020; 194: 101-15. doi:10.1016/j.thromres.2020.06.029.
 17. Hess DC, Eldahshan W, Rutkowski E. COVID-19-related stroke. *Transl Stroke Res.* 2020;11:322-5. doi: 10.1007/s12975-020-00818-9.
 18. McBane RD 2nd, Torres Roldan VD, Niven AS, Pruthi RK, Franco PM, Linderbaum JA, et al. Anticoagulation in COVID-19: A systematic review, meta-analysis, and rapid guidance from Mayo Clinic. *Mayo Clin Proc.* 2020;95:2467-86. doi: 10.1016/j.mayocp.2020.08.030.