

## CASO CLÍNICO/CASE REPORT

## A Novel ACTA2 Gene Disease-Causing Variant Presenting with a Complex Brain Phenotype

## Apresentação de um Fenótipo Cerebral Complexo Causado por uma Nova Variante no Gene ACTA2

 Mafalda Mendes Pinto <sup>1,\*</sup>, Filipa Rodrigues <sup>2,3</sup>, Carmen Costa <sup>3</sup>, Lisete Lopes <sup>4</sup>, Sofia Fernandes <sup>5</sup>,  Isabel Alonso <sup>6</sup>,  Ana Filipa Geraldo <sup>7</sup>, Rui Pedro Pais <sup>1</sup>, Ricardo Veiga <sup>1</sup>,  Filipe Palavra <sup>3,8</sup>

1-Área Funcional de Neurorradiologia, Serviço de Imagem Médica / Centro Hospitalar e Universitário de Coimbra, Portugal

2-Serviço de Pediatria (Aveiro) e Centro de Desenvolvimento da Criança - Neuropediatria (Coimbra) / Centro Hospitalar do Baixo Vouga, Aveiro, Portugal

3-Centro de Desenvolvimento da Criança - Neuropediatria / Hospital Pediátrico - Centro Hospitalar e Universitário de Coimbra, Coimbra, Portugal

4-Serviço de Cardiologia Pediátrica / Hospital Pediátrico - Centro Hospitalar e Universitário de Coimbra, Coimbra, Portugal

5-Serviço de Genética Médica / Hospital Pediátrico - Centro Hospitalar e Universitário de Coimbra, Coimbra, Portugal

6-Instituto de Biologia Molecular e Celular I i3S – Instituto de Investigação e Inovação em Saúde, Universidade do Porto, Porto, Portugal; Genetyca ICM – Instituto de Estudos Celulares e Moleculares, Porto, Portugal

7-Serviço de Neurorradiologia / Centro Hospitalar de Vila Nova de Gaia/Espinho, Vila Nova de Gaia, Portugal

8-Instituto de Investigação Clínica e Biomédica de Coimbra (iCBR), Faculdade de Medicina, Universidade de Coimbra, Coimbra, Portugal

DOI: <https://doi.org/10.46531/sinapse/CC/200032/2020>

## Abstract

ACTA2 is a gene that encodes a smooth muscle (aortic) alpha-actin present in vascular smooth muscle cells, whose function includes contraction and motility of the vessels. Some variants of this gene have been described, causing many systemic problems, including a very characteristic cerebrovascular phenotype. Recently, brain parenchymal abnormalities beyond the classic vascular involvement were described.

We present a 13-year-old girl who came to the Emergency Department with a clinical picture very suggestive of a stroke and whose etiological investigation proved to be very complex, leading to the identification of a totally novel heterozygous c.542A>T; p.(Asp181Val) disease-causing variant in ACTA2 gene. This was associated with a complex brain phenotype, including not only vascular disease, but also recently described parenchymal findings.

This novel disease-causing variant should be considered in patients with cerebrovascular disease and morphological brain parenchymal involvement, as this diagnosis has important therapeutic implications and requires multisystemic surveillance.

## Resumo

O gene ACTA2 codifica uma alfa-actina presente nas células musculares lisas dos vasos, permitindo a sua contractilidade e motilidade. Têm sido descritas variantes deste gene, responsáveis por distúrbios sistémicos, incluindo fenótipo cerebrovascular característico raro. Recentemente, foram descritas alterações estruturais cerebrais parenquimatosas, associadas ao envolvimento da vasculatura.

Apresentamos o caso de uma adolescente de 13 anos que recorreu à Urgência com quadro clínico sugestivo de acidente vascular cerebral, mas cuja investigação etiológica se revelou complexa; identificou-se uma nova variante – c.542A>T; p.(Asp181Val) – causadora de doença, em heterozigotia, no gene ACTA2. Associou-se a um fenótipo cerebral complexo, incluindo não somente doença dos vasos sanguíneos, mas também as alterações parenquimatosas recentemente descritas.

## Informações/Informations:

Caso Clínico, publicado em Sinapse, Volume 20, Número 4, outubro-dezembro 2020. Versão eletrónica em [www.sinapse.pt](http://www.sinapse.pt)

Case Report, published in Sinapse, Volume 20, Number 4, october-december 2020. Electronic version in [www.sinapse.pt](http://www.sinapse.pt)  
© Autor (es) (ou seu (s) empregador (es)) e Sinapse 2020. Reutilização permitida de acordo com CC BY-NC. Nenhuma reutilização comercial. © Author(s) (or their employer(s)) and Sinapse 2020. Re-use permitted under CC BY-NC. No commercial re-use.

## Keywords:

Actins/genetics; Adolescent; Cerebrovascular Disorders/genetics.

## Palavras-chave:

Actinas/genética; Adolescente; Perturbações Cerebrovasculares/genética.

## \*Autor Correspondente / Corresponding Author:

Mafalda Mendes Pinto  
Praceta Prof. Mota Pinto,  
Hospitais da Universidade  
de Coimbra, Serviço de  
Imagem Médica  
3004-561, Coimbra, Portugal  
[mafaldamendespinto@hotmail.com](mailto:mafaldamendespinto@hotmail.com)

Recebido / Received: 2020-06-24

Aceite / Accepted: 2020-10-18

Ahead of Print: 2020-12-21

Publicado / Published: 2021-01-18

Perante doentes que se apresentem com doença cerebrovascular e alterações morfo-estruturais do parênquima cerebral, deve ser considerada a hipótese de doença associada ao gene *ACTA2*, incluindo a nova mutação que descrevemos, porque este diagnóstico tem implicações terapêuticas e necessidade de vigilância multissistémica.

## Introduction

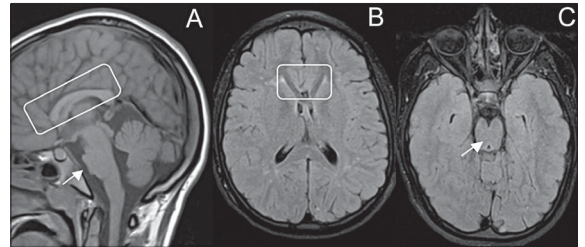
*ACTA2* gene encodes an alpha-actin muscle actin present in vascular smooth muscle cells, whose function includes contraction and motility of the vessels.<sup>1</sup> Different *ACTA2* disease-causing variants were recently described, leading to a variety of systemic diseases, including cardio and cerebrovascular, congenital mydriasis, pulmonary hypertension, gastrointestinal and bladder problems.<sup>2</sup> First disease-causing variants in this gene were described in patients with thoracic aortic aneurysms and/or dissections of the vessel and subsequently many additional cardiovascular malformations extended the phenotype, including early onset coronary artery disease, patent ductus arteriosus and bicuspid aortic valves.<sup>3</sup> Regarding cerebrovascular involvement, a typical imaging pattern characterized by ectasia of proximal and occlusion of terminal internal carotid arteries with straight course of cerebral arteries, absence of moyamoya vessels and white matter microvascular lesions has been initially described, in patients with *ACTA2* variants.<sup>2,4</sup> More recently, D'Arco *et al* described the coexistence of morphological parenchymal findings in patients with the p.(Arg179His) variant.<sup>4</sup>

We report an adolescent with a novel likely pathogenic variant in *ACTA2* gene, whose central nervous system phenotype also includes parenchymal abnormalities beyond the classic vascular involvement.

## Case Report

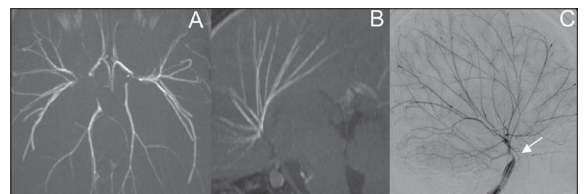
A 13-year-old girl with previous history of patent ductus arteriosus and inter-auricular communication surgically repaired in the first months of life was admitted to the emergency room with global aphasia and mild right hemiparesis. Emergent magnetic resonance imaging (MRI) revealed multiple chronic microvascular white matter lesions, as well as left cortical frontal acute ischemic lesions with diffusion restriction, matching her clinical picture. Nevertheless, many morphological parenchymal abnormalities were also observed: hypoplasia, bending and V-shaping (on axial images) of

anterior corpus callosum, accompanied by deficient anterior *gyrus cinguli* and radial frontal gyration; horizontal orientation and thickening of the fornix; flattening of the pons on the midline, with reduction of its antero-posterior diameter, and multiple indentations in the anterior surface of the midbrain, accompanied by a mild antero-posterior elongation with reduction of the lateral-lateral diameter and squeezing of the cerebral peduncles (**Fig. 1**). MRI-angiography and digital subtraction an-



**Figure 1.** MRI sagittal T1 WI (A) revealed bending and hypoplasia of anterior corpus callosum, deficient anterior *gyrus cinguli*, radial frontal gyration, horizontal orientation and increased thickness of the fornix (inside the box) and flattening of the pons on the midline (arrow) with reduction of the antero-posterior diameter. Axial FLAIR showed (B) V-shaped anterior corpus callosum (inside the box) and antero-posterior elongation of the midbrain with squeezing of the cerebral peduncles (C – arrow).

giography showed stenosis of distal cavernous internal carotids, proximal M1 and A1 segments and diffuse straightening of cerebral arteries in a “twig-like” pattern, with absence of moyamoya-like vessels (**Fig. 2**). This distinctive pattern of cerebrovascular involvement associated with so characteristic brain parenchymal abnormalities raised the suspicion of *ACTA2*-re-



**Figure 2.** MRI angiography TOF (A – axial and B – sagittal MIP reconstructions) and digital subtraction angiography (C – lateral view of internal carotid artery) showed diffuse straightening of cerebral arteries in a “twig-like” pattern, without moyamoya vessels. Stenosis of distal internal carotid arteries was also seen (C – arrow).

lated disease. An extensive morphological and functional cardiac evaluation was performed, revealing no abnormalities. No pulmonary hypertension was detected and no other complaints involving different organs or systems have been reported by the patient. The neurological examination also did not, at any time, identify any relevant pupillary changes.

She was then genetically tested and a novel heterozygous variant (NM\_001613.4: c.542A>T; p.(Asp181Val)) was found in the *ACTA2* gene. Parents were studied and none had the same variant, which was assumed to be *de novo* and classified as likely pathogenic.

## Discussion

Our case supports recent findings that the neuroimaging phenotype associated to *ACTA2* causative variants does not only include characteristic cerebrovascular findings (including “twig-like” artery pattern) and microvascular disease, but also intracranial parenchymal malformations, probably due to, at least in part, increased rigidity of the intracranial arteries.<sup>4</sup> Such parenchymal abnormalities have been previously reported in the corpus callosum, anterior cingulate gyrus, frontal gyrus, fornix, pons and midbrain and, interestingly, they were all present in our patient.<sup>4</sup> Most of the cases reported in the literature with such a complex and similar phenotype result from *ACTA2* Arginine 179 alterations, as illustrated by the case review published in 2018 by Ellen S. Regalado *et al.*<sup>5</sup> Interestingly, our case, despite clinical and imagiologically very similar to the previous ones, results from a different variant, emphasising the genetic complexity of this entity.

In fact, a new variant in *ACTA2* gene was found in our case and assumed to be disease-causing, due to: 1) a compatible clinical phenotype; 2) absence of the identified variant in the asymptomatic parents, which was compatible with the described autosomal dominant transmission pattern associated with this gene; 3) absence in gnomAD, 1000 Genomes, ESP or dbSNP databases; 4) bioinformatic analysis with SIFT, Polyphen-2, Mutation Taster and CADD score predicting it to be deleterious; and 5) a low rate of benign missense variants identified in *ACTA2* gene; missense variants in this gene are commonly associated with disease.

## Conclusion

*ACTA2* variants (and the c.542A>T variant, in particular) should be considered in patients with cerebral arteriopathy. This diagnosis has therapeutic implications, as revascularization seems to be associated with a higher surgical risk than classic moyamoya disease. In addition, clinical surveillance of other organs and systems is required in affected patients, since this is a systemic condition. ■

### Responsabilidades Éticas

Conflitos de Interesse: Os autores declaram a inexistência de conflitos de interesse na realização do presente trabalho.

Fontes de Financiamento: Não existiram fontes externas de financiamento para a realização deste artigo.

Confidencialidade dos Dados: Os autores declaram ter seguido os protocolos da sua instituição acerca da publicação dos dados de doentes.

Consentimento: Consentimento do doente para publicação obtido.

Proveniência e Revisão por Pares: Não comissionado; revisão externa por pares.

### Ethical Disclosures

Conflicts of Interest: The authors have no conflicts of interest to declare.

Financing Support: This work has not received any contribution, grant or scholarship.

Confidentiality of Data: The authors declare that they have followed the protocols of their work center on the publication of data from patients.

Patient Consent: Consent for publication was obtained.

Provenance and Peer Review: Not commissioned; externally peer reviewed.

### References / Referências

1. Shi-Min Y.  $\alpha$ -Smooth muscle actin and *ACTA2* gene expressions in vasculopathies. *Braz J Cardiovasc Surg.* 2015;30:644-9. doi: 10.5935/1678-9741.20150081.
2. Munot P, Saunders DE, Milewicz DM, Regalado ES, Ostergaard JR, Braun KP, et al. A novel distinctive cerebrovascular phenotype is associated with heterozygous Arg179 *ACTA2* mutations. *Brain.* 2012;135:2506-14. doi: 10.1093/brain/aww172.
3. Meuwissen ME, Lequin MH, Bindels-de-Heus K, Bruggenwirth HT, Knapen MF, Dalinghaus M, et al. *ACTA2* mutation with childhood cardiovascular, autonomic and brain anomalies and severe outcome. *Am J Med Genet A.* 2013;161A:1376-80. doi: 10.1002/ajmg.a.35858.
4. D'Arco F, Alves CA, Raybaud C, Chong WK, Ishak GE, Ramji S, et al. Expanding the distinctive neuroimaging phenotype of *ACTA2* mutations. *AJNR Am J Neuroradiol.* 2018;39:2126-31. doi: 10.3174/ajnr.A5823.
5. Regalado ES, Mellor-Crummey L, De Backer J, Braverman AC, Ades L, Benedict S, et al. Clinical History and Management Recommendations of the Smooth Muscle Dysfunction Syndrome Due to *ACTA2* Arginine 179 Alterations. *Genet Med.* 2018; 20:1206–15. doi:10.1038/gim.2017.245.