

CASO CLÍNICO/CASE REPORT

Post-Malaria Neurological Syndrome: A Rare Complication Following *Plasmodium falciparum* Infection**Síndrome Neurológica Pós-Malária: Complicação Rara Após Infecção por *Plasmodium falciparum***Andreia Fernandes*¹, Diana Melancia^{1,2}, Ana Calado¹, Margarida Dias¹, Isabel Henriques¹

1-Centro Hospitalar Universitário de Lisboa Central, Departamento de Neurologia.

2-Universidade de Lisboa, Faculdade de Medicina, Departamento de Farmacologia e Neurociências.

Informações/Informations:

Caso Clínico, publicado em Sinapse, Volume 19, Número 1-2, janeiro-março · abril-junho 2019. Versão eletrónica em www.sinapse.pt
Case Report, published in Sinapse, Volume 19, Number 1-2, January-March · April-June 2019. Electronic version in www.sinapse.pt

© Autor (es) (ou seu (s) empregador (es)) 2019. Reutilização permitida de acordo com CC BY-NC. Nenhuma reutilização comercial.

© Author(s) (or their employer(s)) 2019. Re-use permitted under CC BY-NC. No commercial re-use.

Palavras-chave:

Encefalopatias/etiologia; Malária; Falciparum/complicações; Plasmodium falciparum; Síndrome.

Keywords:

Brain Diseases/etiology; Malaria; Falciparum/complications; Plasmodium falciparum; Syndrome.

***Autor Correspondente / Corresponding Author:**

Andreia Fernandes
Centro Hospitalar de Lisboa Central
Department of Neurology
Alameda de Santo António dos Capuchos,
1169-050 Lisboa, Portugal
andreiafernandes@hotmail.com

Recebido / Received: 2018-10-18
Aceite / Accepted: 2019-02-26

Resumo

Introdução: A síndrome neurológica pós-malária é uma complicação rara da malária. É uma complicação monofásica caracterizada por sintomas neurológicos e/ou psiquiátricos transitórios que ocorrem nos dois meses seguintes à recuperação completa do episódio de malária. Desde a primeira descrição em 1996, menos de 50 casos foram reportados, a sua maioria ocorrendo após infeções graves por *Plasmodium falciparum*. A ocorrência da síndrome após um episódio de malária não complicado é muito rara, com apenas três casos descritos na literatura.

Caso Clínico: Descrevemos um caso de um homem de 59 anos, caucasiano, residente em Luanda (Angola), que desenvolveu um quadro de cefaleias seguidas de alteração do estado mental com confusão e alteração do comportamento três semanas após a recuperação completa de uma infeção por *Plasmodium falciparum* tratada com quinino e doxiciclina. O esfregaço de sangue periférico e exame de gota espessa foram negativos. A análise do líquido cefalorraquidiano revelou aumento da concentração de proteínas (65,5 mg/dL) e 8 linfócitos/ μ L. A ressonância magnética crânio-encefálica não mostrou alterações e o eletroencefalograma mostrou lentificação difusa da eletrogénese de base com atividade delta rítmica frontal intermitente. Após a exclusão de uma causa infecciosa presumiu-se o diagnóstico de síndrome neurológica pós-malária e o doente foi tratado com metilprednisolona 1 g/dia durante 5 dias, com recuperação completa nos 5 dias seguintes.

Conclusão: A encefalopatia responsiva à corticoterapia ocorrendo 3 semanas após a recuperação completa de um episódio de malária é consistente com o diagnóstico de síndrome neurológica pós-malária. Este é um caso raro que se acrescenta aos três casos descritos na literatura de síndrome neurológica pós-malária após infeção por *Plasmodium falciparum* não complicada.

Abstract

Introduction: Post-malaria neurological syndrome is a rare complication of malaria. It is a monophasic complication characterized by transient neurological and/or psychiatric symptoms occurring within two months following a complete recovery from an episode of malaria. Since the first description in 1996, less than 50 cases have been reported, mostly following cases of severe *Plasmodium falciparum* infection. The occurrence of the syndrome following uncomplicated malaria is very rare, with only three reports available in the literature.

Case Report: We report a case of a 59-year-old caucasian male living in Luanda (Angola) who developed headaches followed by altered mental status with confusion and behaviour change three weeks after complete recovery from an uncomplicated *Plasmodium falciparum* infection treated with quinine and doxycycline. Peripheral blood smear and thick blood film examination showed no parasites. Cerebral spinal fluid analysis showed increased protein concentration (65.5 mg/dL) and 8 lymphocytes/ μ L. Brain magnetic resonance imaging was unremarkable and electroencephalography showed diffuse slowing of the background activity with frontal intermittent rhythmic delta activity. After the exclusion of an infectious cause, it was treated for presumed post-malaria neurological syndrome (methylprednisolone 1 g/day during 5 days) with complete recovery during the following 5 days.

Conclusion: An encephalopathy responsive to steroid therapy occurring 3 weeks after complete recovery from a malaria episode is consistent with the post-malaria neurological syndrome diagnosis. This is a rare case to add to the three cases described in the literature of post-malaria neurological syndrome following uncomplicated malaria.

Introduction

The post-malaria neurological syndrome (PMNS) was first described by Nguyen and colleagues in 1996 through a prospective study conducted in two centres from Vietnam and Thailand.¹ In this study, that included 18 124 patients with *Plasmodium falciparum* infection, 1 176 fulfilling criteria for severe malaria, PMNS was observed in 19 adults and 3 children. Only in one of the 22 patients PMNS followed uncomplicated malaria.

After this first description, additional cases have been subsequently reported, defining the clinical features of PMNS.²⁻²¹ As observed in the series reported by Nguyen and colleagues almost all these new cases met criteria for severe malaria with only two reports occurring after uncomplicated malaria.^{14,16}

The criteria for PMNS diagnosis defined by Nguyen and colleagues were: 1. Recent symptomatic malaria infection with parasites cleared from peripheral blood; 2. In cases of cerebral malaria, full recovery of consciousness; 3. Development of neurological or psychiatric symptoms within two months after the acute illness. This later distinguishes it from cerebral malaria, which occurs during parasitemia.

The clinical spectrum of PMNS is broad and self-limiting, lasting from 2-14 days without any specific treatment.^{1,12}

Schnorf *et al*² proposed in 1998 a classification into 3 subtypes of PMNS according to the severity of symptoms: 1. A mild and localized encephalopathy affecting

the cerebellum and causing isolated cerebellar ataxia or postural tremor (called delayed cerebellar syndrome); 2. A diffuse but not severe encephalopathy causing confusion with or without epileptic seizures; 3. A severe generalized encephalopathy with a good response to steroid therapy.

The most common features described included decreased level of consciousness, confusion, fever, generalized seizures, aphasia, tremor, psychosis and myoclonus. Less common manifestations include headache, ataxia, weakness, catatonia, acalculia and ophthalmoplegia. The symptoms arise in a variable time after the infection, lasting from 2 up to 60 days after the disappearance of the parasitemia.^{1,12}

Schnorf and colleagues described two cases of severe PMNS in which the patients developed progressive encephalopathy, seizures, myoclonus, and ataxia.² In both patients corticosteroid therapy was instituted, 9 and 12 days respectively after the onset of the neurological symptoms, with improvement of neurological symptoms from the first day of treatment. Since then, corticosteroids have been used in severe cases with good clinical outcomes.^{4,8,11,12,15}

The pathogenesis is still unknown. Several factors suggest that PMNS may be immunologically mediated. The delay between the recovery of acute malarial infection and the onset of PMNS symptoms, as well as the favourable response to corticosteroids support this hypothesis. Some studies have shown an increased se-

rum and CSF concentrations of certain inflammatory cytokines like tumor necrosis factor- α , interleukin-2 and interleukin-6, that decreases after corticotherapy in patients with post malaria cerebellar ataxia, also suggesting a role of immunological activation in PMNS.^{4,22}

The risk factors for the development of PMNS are not yet fully understood, however, severe *Plasmodium falciparum* malaria and treatment with mefloquine have been associated to this complication.

In the series reported by Nguyen et al in Vietnam, all cases followed infection with *Plasmodium falciparum* and none followed *Plasmodium vivax* infection although this parasite accounts for about 30% of malaria infections seen at the site of the study. Since then, most reported cases of PMNS followed recovery from *falciparum* malaria and only a few cases have been reported with *Plasmodium vivax*.¹⁸ Therefore, *Plasmodium falciparum* infection has been considered a risk factor for PMNS.

Nguyen et al reported an incidence of PMNS in malaria patients of 1.2 per 1000 patients and an increase to 1.8 per 100 patients in the most severe cases, being this syndrome 300 times more frequent in patients with severe rather than uncomplicated malaria. In the same study the authors noted an association between treatment with mefloquine and development of PMNS, with a relative risk compared to treatment with quinine of 9.2 (1.2-71.3; $p=0.012$), and also a synergistic neurotoxicity between the drug and the disease, which increases with the severity of the infection. This data led the authors to suggest a role for mefloquine in the aetiology of this syndrome. However, this did not account for all cases and other cases occurring in patients treated with other antimalarials were reported.^{2-6,10,11}

Case Report

A 59-year-old caucasian male living in Luanda (Angola), previously healthy, was admitted into a private hospital (Clínica Sagrada Esperança) in Luanda, with a

5-day history of asthenia, prostration, fever, chills and myalgias (Fig. 1). Diagnosis of malaria was made based on the clinical symptoms and a peripheral blood smear that revealed the presence of *Plasmodium falciparum* (150 parasites/field). He started treatment with quinine and doxycycline. Symptoms progressively disappeared, with apyrexia at day 5. There was a progressive decline in parasitemia measured every day, with 11 parasites/field on day 4. After 7 days of treatment the patient was discharged with full clinical recovery and negative parasitemia. Because the patient listened to a second opinion after discharge he took 3 more days of quinine and doxycycline. There was no previous diagnosis of malaria in the patient.

After 3 weeks free of symptoms, the patient developed headaches followed by an altered mental status with confusion, apathy, language difficulties, and periods of motor agitation and inappropriate behaviour. He repeated blood tests for *Plasmodium falciparum* that were negative and he did a computed tomography (CT) scan reported as normal. No medication was prescribed at this time. In the absence of improvement of symptoms after 5 days, the relatives chose to seek medical care in Portugal.

Six days after the onset of symptoms he was admitted to our hospital in Portugal. The neurologic examination revealed prominent inattention, spatial and temporal disorientation and language impairment with paucity of spontaneous speech, impaired naming and difficulty in understanding simple questions and commands. The rest of the systemic examination was unremarkable. On the day of admission, the rapid malaria antigen test was positive for *Plasmodium falciparum* but repeated peripheral blood smears and thick blood film examination were negative for ring forms of *Plasmodium falciparum*, which was consistent with the recently treated malaria episode. Cerebrospinal fluid (CSF) analysis revealed 8 lymphocytes/ μ l, increased protein concentration of 65.5

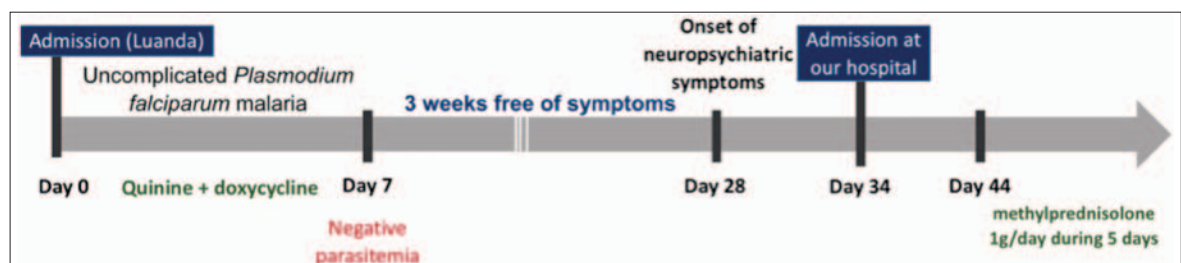


Figure 1. Clinical case timeline.

mg/dL, and a glucose level of 53 mg/dL. Empiric treatment with acyclovir (750 mg IV 8/8 hours) was started and maintained over 6 days, until CSF polymerase chain reaction (PCR) testing for herpes virus was reported negative. No evidence of central nervous system infection was found, with negative CSF cultures and CSF PCR testing for common neurotropic viruses (Herpes simplex viruses, human herpesviruses, varicella-zoster virus, Epstein-Barr virus, cytomegalovirus, enterovirus and parvovirus). Blood cultures and serologic tests for Hepatitis B and C, human immunodeficiency virus type 1 and 2, VDRL, Huddleson test and *Borrelia burgdorferi* antibodies were negative.

Computed tomography and magnetic resonance imaging (MRI) of the brain was unremarkable. Electroencephalography showed diffuse slowing of the background activity with frontal intermittent rhythmic delta activity consistent with a diffuse encephalopathy.

After the exclusion of an infectious cause, PMNS was presumed and methylprednisolone (1 g/day during five days) was initiated on the 10th day of hospitalization with complete recovery during the following 5 days.

Discussion

In this case, the onset of neuropsychiatric symptoms 3 weeks after a complete recovery from *Plasmodium falciparum* malaria is consistent with the PMNS diagnosis. Cerebral malaria was excluded by negative peripheral blood smears and thick blood film examination.

We found no laboratory evidence of other infectious diseases, namely viral or bacterial causes of meningoencephalitis. However, tests for other viruses described in Angola, notably arboviruses, were not performed. Arboviruses are responsible for causing a wide spectrum of clinical syndromes, ranging from mild to severe febrile illness to neuroinvasive disease. The neuroinvasive disease is usually characterized by an acute onset of fever with headache, myalgia, neck stiffness, altered mental status, seizures, and limb weakness.²³ In our case, the 3-week symptom-free interval between acute febrile illness and the emergence of neuropsychiatric symptoms is not suggestive of neuroinvasive arbovirus infection. The neuropsychiatric clinical picture that motivated hospitalization in Portugal with its long course and absence of other arboviral disease symptoms, such as myalgia, rash, arthralgia, vomiting, paresis or stiff neck, also makes this hypothesis less likely.

Also no metabolic abnormalities were found that could cause confusion or neurological dysfunction.

It is unlikely that the patient's symptoms were due to the toxic effect of antimalarial treatment. Quinine intoxication results in hypokalaemia, hypoglycaemia, cardiotoxicity, visual symptoms and neurological features such as convulsions, coma and ataxia that develop during or shortly after the usage of quinine.²⁴ Except for the neurological symptoms our patient did not have any of the symptoms mentioned above neither was still in treatment with quinine.

The patient was also treated with doxycycline, and some authors have previously reported an association between tetracycline use and "benign intracranial hypertension".²⁵ Symptoms usually begin during treatment and include headache, blurred vision, diplopia and vision loss. With the exception of the initial headache, there were no other signs or symptoms suggestive of intracranial hypertension associated with doxycycline use in this case.

MRI of the brain and spinal cord in PMNS may be normal or may show widespread white matter lesions.^{3,5,11,12} In the present case the results of CT scan and MRI were normal.

As in this case, the examination of CSF lumbar puncture often demonstrates a lymphocytic pleocytosis and elevated protein concentration.^{1,12}

Ten days after the onset of the encephalopathy the patient showed no signs of spontaneous recovery. Corticosteroid therapy was then instituted and rapid improvement was observed from the first day of treatment, with complete recovery during the following 5 days.

The development of neurological symptoms 3 weeks after recovery of *Plasmodium falciparum* infection, the mild mononuclear pleocytosis and increased concentration of proteins detected in CSF and the favourable clinical response to corticosteroid therapy in our patient are suggestive of an underlying immune mechanism.

This is a case of PMNS following an uncomplicated *Plasmodium falciparum* infection whose presentation was an encephalopathy that responded to steroid treatment. This is a rare case to add to the three cases described in the literature of PMNS following uncomplicated malaria. ■

Responsabilidades Éticas

Conflito de Interesses: Os autores declaram não ter conflitos de interesse na realização do presente trabalho

Fontes de Financiamento: Não existiram fontes externas de financiamento para a realização deste artigo.

Confidencialidade dos Dados: Os autores declaram ter seguido os protocolos do seu centro de trabalho acerca da publicação dos dados de doentes.

Proveniência e Revisão por Pares: Não comissionado; revisão externa por pares.

Ethical Disclosures

Conflicts of Interest: The authors report no conflict of interest.

Funding Sources: No subsidies or grants contributed to this work.

Confidentiality of Data: The authors declare that they have followed the protocols of their work center on the publication of patient data.

Provenance and Peer Review: Not commissioned; externally peer reviewed.

References

1. Nguyen TH, Day NP, Ly VC, Waller D, Mai NT, Bethell DB, et al. Post-malaria neurological syndrome. *Lancet*. 1996;348:917-21.
2. Schnorf H, Diserens K, Schnyder H, Chofflon M, Loutan L, Chaves V, et al. Corticosteroid-responsive postmalaria encephalopathy characterized by motor aphasia, myoclonus, and postural tremor. *Arch Neurol*. 1998;55:417-20.
3. Mohsen AH, McKendrick MW, Schmid ML, Green ST, Hadjivassiliou M, Romanowski C. Postmalaria neurological syndrome: a case of acute disseminated encephalomyelitis? *J Neurol Neurosurg Psychiatry*. 2000;68:388-9.
4. Lawn SD, Flanagan KL, Wright SG, Doherty TF, Godfrey-Faussett P. Postmalaria neurological syndrome: two cases from the Gambia. *Clin Infect Dis*. 2003;36:e29-31.
5. Falchook GS, Malone CM, Upton S, Shandera WX. Postmalaria neurological syndrome after treatment of *Plasmodium falciparum* malaria in the United States. *Clin Infect Dis*. 2003;37:e22-4.
6. Palmieri F, Petrosillo N, Paglia MG, Conte A, Goletti D, Pucillo LP, et al. Genetic confirmation of quinine-resistant *Plasmodium falciparum* malaria followed by postmalaria neurological syndrome in a traveler from Mozambique. *J Clin Microbiol*. 2004;42:5424-6. doi: 10.1128/JCM.42.11.5424-5426.2004.
7. Zambito Marsala S, Ferracci F, Cecotti L, Gentile M, Conte F, Candeago RM, et al. Post-malaria neurological syndrome: clinical and laboratory findings in one patient. *Neurol Sci*. 2006;27:442-4. doi: 10.1007/s10072-006-0728-2.
8. van der Wal G, Verhagen WI, Dofferhoff AS. Neurological complications following *Plasmodium falciparum* infection. *Neth J Med*. 2005;63:180-3.
9. Mizuno Y, Kato Y, Kanagawa S, Kudo K, Hashimoto M, Kunitomo M, et al. A case of postmalaria neurological syndrome in Japan. *J Infect Chemother*. 2006;12:399-401. doi: 10.1007/s10156-006-0489-0.
10. Prendki V, Elziere C, Durand R, Hamdi A, Cohen Y, Onnen I, et al. Post-malaria neurological syndrome--two cases in patients of African origin. *Am J Trop Med Hyg*. 2008;78:699-701.
11. Matias G, Canas N, Antunes I, Vale J. Post-malaria neurological syndrome. *Acta Med Port*. 2008;21:387-90.
12. Markley JD, Edmond MB. Post-malaria neurological syndrome: a case report and review of the literature. *J Travel Med*. 2009;16:424-30. doi: 10.1111/j.1708-8305.2009.00349.x.
13. Odawara T, Matsumura T, Maeda T, Washizaki K, Iwamoto A, Fujii T. A case of post-malarial neurological syndrome (PMNS) after treatment of falciparum malaria with artesunate and mefloquine. *Trop Med Health*. 2009;37:125-8.
14. Forestier E, Labe A, Raffenet D, Lecomte C, Rogeaux O. Post-malaria neurological syndrome complicating a relapse of *Plasmodium falciparum* malaria after atovaquone-proguanil treatment. *Med Mal Infect*. 2011;41:41-3. doi: 10.1016/j.medmal.2010.07.007.
15. Motta LP, Costa MA, Gouvea MB, Tibúrcio AS, João Filho EC, Specterow M, et al. Postmalaria neurological syndrome: a case report. *Rev Soc Bras Med Trop*. 2011;44:787-8.
16. Rakotoarivelo RA, Razafimahefa SH, Andrianasolo R, Fandresena FH, Razanamparany MM, Randria MJ, et al. Post-malaria neurological syndrome complicating a *Plasmodium falciparum* malaria in Madagascar. *Bull Soc Pathol Exot*. 2012;105:199-201. doi: 10.1007/s13149-012-0208-7.
17. Gómez Viera N, Olivera Leal IR, Ruiz García D, Santana Chill L, Río Bazán D, León Castellón R. Postmalaria neurological syndrome. *Rev Cubana Med*. 2014;53:354-8.
18. Mittal S, Misri ZK, Rakshith KC, Mittal S. Post malarial neurological syndrome: an uncommon cause. *J Neuroinfect Dis*. 2015;S1:004.
19. Costa A, Silva-Pinto A, Alves J, Neves N, Martínez-Hernández E, Abreu P, et al. Postmalaria neurologic syndrome associated with neurexin-3alpha antibodies. *Neurol Neuroimmunol Neuroinflamm*. 2017;4:e392. doi: 10.1212/NXI.0000000000000392.
20. Chiabi A, Bogne JB, Nguéack S, Guillot H, Caumes E, Jauréguiberry S. Post malaria neurological syndrome in a Cameroonian child after a *Plasmodium falciparum* malaria infection. *J Public Health Emerg*. 2017;1:6.
21. Siriez JY, Prendki V, Dauger S, Michel JF, Blondé R, Faye A, et al. Post-malaria neurologic syndrome: a rare pediatric case report. *Pediatr Infect Dis J*. 2017;36:1217-9. doi: 10.1097/INF.0000000000001661.
22. de Silva HJ, Hoang P, Dalton H, de Silva NR, Jewell DP, Peiris JB. Immune activation during cerebellar dysfunction following *Plasmodium falciparum* malaria. *Trans R Soc Trop Med Hyg*. 1992;86:129-31.
23. Lyons JL. Viral Meningitis and Encephalitis. *Continuum*. 2018;24:1284-97. doi: 10.1212/CON.0000000000000650.
24. Liles NW, Page EE, Liles AL, Vesely SK, Raskob GE, George JN. Diversity and severity of adverse reactions to quinine: A systematic review. *Am J Hematol*. 2016;91:461-6. doi: 10.1002/ajh.24314.
25. Digre KB. Not so benign intracranial hypertension. *BMJ*. 2003;326:613-4. doi: 10.1136/bmj.326.7390.613.